Brain Research Bulletin 77 (2008) 327–334

Contents lists available at ScienceDirect

Brain Research Bulletin

journal homepage: www.elsevier.com/locate/brainresbull

Review

Cerebrospinal fluid outflow: An evolving perspective

Kapil G. Kapoor[a,c,*], Steven E. Katz[a,b], Deborah M. Grzybowski[a,b], Martin Lubow[a]

[a] Department of Ophthalmology, The Ohio State University, Columbus, OH, United States
[b] Department of Biomedical Engineering, The Ohio State University, Columbus, OH, United States
[c] Department of Ophthalmology and Visual Sciences, University of Texas Medical Branch at Galveston, Galveston, TX, United States

ARTICLE INFO

Article history:
Received 15 June 2008
Accepted 8 August 2008
Available online 13 September 2008

Keywords:
Cerebrospinal fluid
Outflow
Egress
Arachnoid granulation
Lymphatic

ABSTRACT

Cerebrospinal fluid (CSF) serves numerous important functions in the central nervous system. Despite numerous reports characterizing CSF and its circulation in the subarachnoid space, our understanding of CSF outflow remains limited. Although initial work suggested that both arachnoid granulations and lymphatic capillaries shared in the role of CSF outflow, predominant work since then has focused on the arachnoid granulations. A growing body of recent evidence not only suggests the importance of both arachnoid granulations and lymphatic capillaries, but also additional contributions through transependymal passage likely share in the role of CSF outflow. Consideration of all mechanisms and pathways will help us to better understand the significance of CSF outflow, in health and disease. Here we review how the present concept of CSF outflow has evolved, including a historical review of significant findings and a discussion of the latest innovative developments.

Contents

1. Introduction to cerebrospinal fluid

Cerebrospinal fluid (CSF) is a clear, bright fluid circulating through the subarachnoid space and providing a neuroprotective function as a hydraulic cushion for the brain and spinal cord. It likely also serves metabolic, nutritional, immunologic, and scavenging functions for the central nervous system. CSF is produced primarily in the choroid plexuses of the cerebral ventricles, flows through the subarachnoid space, and eventually returns to the venous system.

Despite an extensive CSF literature, a satisfactory review of the major outflow pathways of CSF from the subarachnoid space is not yet at hand. Most CSF research to date has been directed to CSF production and circulation. CSF outflow has been studied, but this research has focused mostly on animals, leaving our knowledge of human CSF outflow physiology incomplete. Furthermore, the few studies that have addressed human CSF outflow have emphasized anatomic and morphologic characteristics of these pathways, leaving functional attributes still poorly understood.

* Corresponding author at: 9420 Seawall Boulevard Unit 304, Galveston, TX 77554, United States. Tel.: +1 440 590 1391; fax: +1 440 835 1992.
E-mail address: kaps2003@gmail.com (K.G. Kapoor).

0361-9230/$ – see front matter © 2008 Elsevier Inc. All rights reserved.
doi:10.1016/j.brainresbull.2008.08.009

Despite these gaps in our knowledge, it is evident that our understanding of CSF outflow has evolved since initial work in this field. A timeline of landmark publications on CSF outflow is presented in Table 1, clearly tracing this evolution. It is notable that in addition to demonstrating an outflow pathway via the arachnoid granulations, concurrent work, since 1869, has shown a significant lymphatic pathway in animals as well [39].

Although physiologists know otherwise, physicians in the course of their training in neuroanatomy are prone to believe that the arachnoid granulations are solely responsible for the burden of CSF outflow. Some, more enlightened, call this view arachnocentric. Current thinking suggests that both the arachnoid granulations and the lymphatic pathways share in cerebrospinal fluid absorption [23,32]. Indeed, in limited conditions of disease with high pressure, a third route of transependymal outflow has also been described.

Despite the limited number of studies specifically addressing human CSF outflow, it is still clear that the arachnoid granulations are not the only CSF outflow pathway. Consideration of both arachnoid and lymphatic pathways will help us to better understand the mechanisms and significance of CSF outflow, in health and disease.

2. The arachnoid granulation in cerebrospinal fluid outflow

2.1. Introduction

Pacchioni (1721) first described the arachnoid granulations as "peculiar wartlike excrescences [35]." Initial experimental work on CSF outflow, however, is credited to Key and Retzius' landmark study in 1876 [25]. Weed in 1914 describes their work in detail, in which they injected gelatine solutions colored with Berlin blue into the spinal subarachnoid space of human cadavers "at fairly low pressures (60 mmHg) [46]." The injected masses "passed through the Pacchionian granulations (die Arachnoidenzotten of Luschka) into the cerebral sinus," and also into the "lymphatic vessels in the frontal sinus, in the nasal mucous membrane, and elsewhere." This is the first suggestion of a dual system of CSF drainage.

2.2. Morphology of the arachnoid granulation

Weed further directed his investigations to the structure of arachnoid granulations [46]. He described the granulation as a "delicate web-like structure of many interlacing cords", covered by a layer of mesothelial cells, and serving as a continuation of the outer arachnoid membrane into the dura. Weed also suggested that the arachnoid granulations were exaggerations of the much smaller arachnoid villi he found to be prevalent in animals. Le Gros Clark (1920) proposed that arachnoid granulations develop from arachnoid villi, and he also further characterized the structure, development, and distribution of arachnoid granulations [29]. His work showed that although human arachnoid villi are imperceptible at birth, they are obvious by 18 months, first visible where the parieto-occipital and central veins open into the superior sagittal sinus. Arachnoid villi eventually spread over a considerable area by 3 years of age, and may be seen along the lateral sinus. By 4 years of age, they are noticeable at the superior sagittal sinus, where they ultimately develop with greatest frequency [29].

Light microscopy later allowed a closer examination of the arachnoid villus, this time in the monkey, elucidating important morphological and functional attributes [47]. In this study, Welch and Friedman described the villus as a labyrinth of coated tubes, 4–12 μm in diameter, attributed to prolongations of arachnoid cells. They further suggested interconnections existed between these tubes, with dual openings into the subarachnoid space and venous channels, depicting this important connection for the first time.

The open communication between the arachnoid villi and venous channels in monkeys were further studied by Welch and Pollay. They perfused arachnoid villi and demonstrated passage of colloidal gold, yeast, and goat and monkey erythrocytes. Particles of larger dimension became enmeshed in the arachnoid villi and led to impedance of flow, further suggesting the anatomic importance of the villi [48].

In the 1970s work was directed toward the prominent cap of the arachnoid granulation and its possible functional attributes. An intact endothelial layer was found covering the arachnoid villus in primates and canines, with an interendothelial cleft sealed by tight junctions, preventing protein passage [1,41,44]. Protein transport was attributed to phagocytosis within the villus. These findings suggested that CSF outflow may require metabolic activity by the endothelial cells of the arachnoid villi. However, direct evidence of active transport at the level of the endothelial cells remains to be conclusively demonstrated.

Tripathi described transdural openings 100 μm in diameter leading to transdural channels of smaller caliber connecting the subdural space with the lumen of the dural sinus or its lacunae [44]. He also demonstrated large pores on the surface of the endothelial cells, and proposed a vacuolar mechanism of CSF passage via these cells.

A perfusion study in monkeys by Levine in 1982 looked at structures in arachnoid villi and found that their appearance was affected by CSF flow [31]. Increased CSF flow was associated with increased vacuoles, channels, or pores in the villi, whereas no CSF flow showed a complete absence of such structures. This study demonstrated a dynamic adaptability of the AG structure, with important functional implications in CSF outflow physiology.

A morphological characterization of the CSF drainage pathway in the arachnoid granulation of rabbits was done by Upton et al. in 1985 [45]. Using light microscopy and SEM he showed that the apical cap is approximately 150 μm thick and surmounts a collagenous core, with endothelial-lined channels extending through the cap (to reach subendothelial regions of the granulation). "The cap region of the granulation is only attached to the endothelium over an area 300 μm in diameter." Scanning electron microscopy also revealed "an intact endothelial surface to the granulations with small perforating venous channels present on the apex." This confirmed previous findings on the intact endothelial layer and contributed structural measurements of the arachnoid granulation [41,13].

CSF egress through arachnoid granulations had been studied primarily in animal models, a major limitation since it was unknown how well animal models correlated with human anatomy. D'Avella's study in 1983 was important in changing this trend, as he used EM to study human arachnoid granulations [13]. This study confirmed the presence of many ultrastructural findings in humans that had been "previously identified in animals," such as "gaps between endothelial cells, and tubule-like endothelium-lined structures."

Further work continued to focus on characterizing the arachnoid cap in humans. An important study by Yamashima et al. using electron microscopy showed that despite other similarities, the human arachnoid cap cell covering is markedly different than animal models [52]. The arachnoid cell covering contains an electron-lucent outer zone and an electron-dense inner zone, and "the outer zone has less cytoplasmic filaments and desmosomes than the inner zone." The absence of "free communications such as endothelial open junctions or endothelium-lined tubules" was also reported [53]. This suggested that "extracellular cisterns of the arachnoid cell layer contribute to the passive transport of CSF, whereas micropinocytosis and vacuolization are available for active transport."

Table 1
Timeline of landmark publications in CSF outflow

Year	Author	Species	Method	Major finding
1721	Pacchioni	Human	Observation	First describes the arachnoid granulations as "peculiar wart-like excrescences".
1876	Key, Retzius	Human cadavers	Tracer study	First finds gelatine tracer in arachnoid granulations and lymphatics.
1914, 1917	Weed	Humans	Light microscopy	First extensive characterization of arachnoid villus.
1920	Clark	Humans	Observation	First characterization of the AG development and distribution.
1948, 1950	Brierley and Field	Rabbits	Carbon particle injection	First demonstration of systemic nature of CSF drainage by injection of a suspension of carbon particles of varying sizes (.4–1.5 um) into the lateral ventricles over varying time periods (1–108 h), finding some clustered in nerve roots of lumbosacral and cervical regions (the ink cuff).
1951	Courtice, Simmonds	Cats and rabbits	Plasma injection with Evans blue dye	Injected Evans Blue into the cisterna magna of cats and rabbits and showed that the labeled proteins appeared in blood plasma and in the lymph. Lymph amount much less than plasma – first quantitative assessment of this interplay.
1970	Czerniawska	Rabbit	Au^{198} injection	First indication of retrograde flow of CSF into the anterior cranial fossa.
1973	Tripathi	Monkey	Electron microscopy	Described vacuoles in mesothelial lining of arachnoid mater that dynamically formed to allow passage of CSF across the tight-junction barriers of the endothelial covering of the AG.
1972	Alksne, Lovings	Adult mongrel dogs	Tracer study	First suggested an intact endothelium separating the arachnoid villi from the superior sagittal sinus. Found injected horseradish peroxidae accumulates beneath the endothelial basement membrane, and zona occludens limit tracer in intercellular junctions.
1980	Bradbury, Cole	Rabbits/cats	Tracer study ([^{125}I] albumin and fluorescent dextran)	Injection of radio-iodinated albumin and fluorescent dextran (20 μl/min) over 6–8 h into lateral ventricles yields first quantitative assessment of lymphatic CSF drainage. 30% or more of CSF drains into deep cervical lymphatic system of the rabbit (at rate of 2.3 μl/min), and 10–15% drains in the cat (at rate of 5.0 μl/min). Radioactivity of albumin and fluorescence of dextran reached plateaus in cat deep cervical lymph at 47.4 and 50% of their concentrations, respectively.
1986, 1988	Yamashima	Human	Electron microscopy	Showed human AG very different from animal AG; arachnoid cell covering contains an electron-lucent outer zone and an electron-dense inner zone, and the outer zone has less cytoplasmic filaments than the inner zone; further characterize AG as lacking free communications such as endothelial open junctions or endothelium-lined tubules.
1988	Kida	Human	EM and immunohistochemistry	Extensively characterized human AG; outlined four major parts: a central core, composed of arachnoid cells and fibroblasts interspersed in a connective tissue matrix; a fibrous capsule covers the arachnoid cell layer except at the apical portion of the granulation.
1993	Kida, Pantazis, Weller	Male Wistar Rats	*In vivo* (injection of India Ink into cisterna magna)	Ink was found in SAS of optic nerve as well as cochlea, but directly communicated only with nasal mucosa and associated lymphatics. Ink reach the deep cervical nodes within 30 min of injection.
1996	Boulton et al.	Sheep	*In vivo*	Elucidates olfactory, optic, trigeminal, and auditory nerve pathways, showing multiple lymphatic pathways of CSF drainage directed primarily toward retropharyngeal/cervical lymph nodes.
2002	Ohta	Humans, canines, primates	Immunohistochemistry and SEM	AG of primates and canines are completely invested with an endothelial covering from the venous lumen, whereas human AG show a cap cell layer in direct contact with the venous lumen.
2003	Zakharov et al.	Lambs	*In vivo*	Microfil infusion was used to trace the lymphatic CSF drainage pathways. CSF absorption takes place at innumerable extracranial locations, with extensive communication between CSF and lymph nodes.

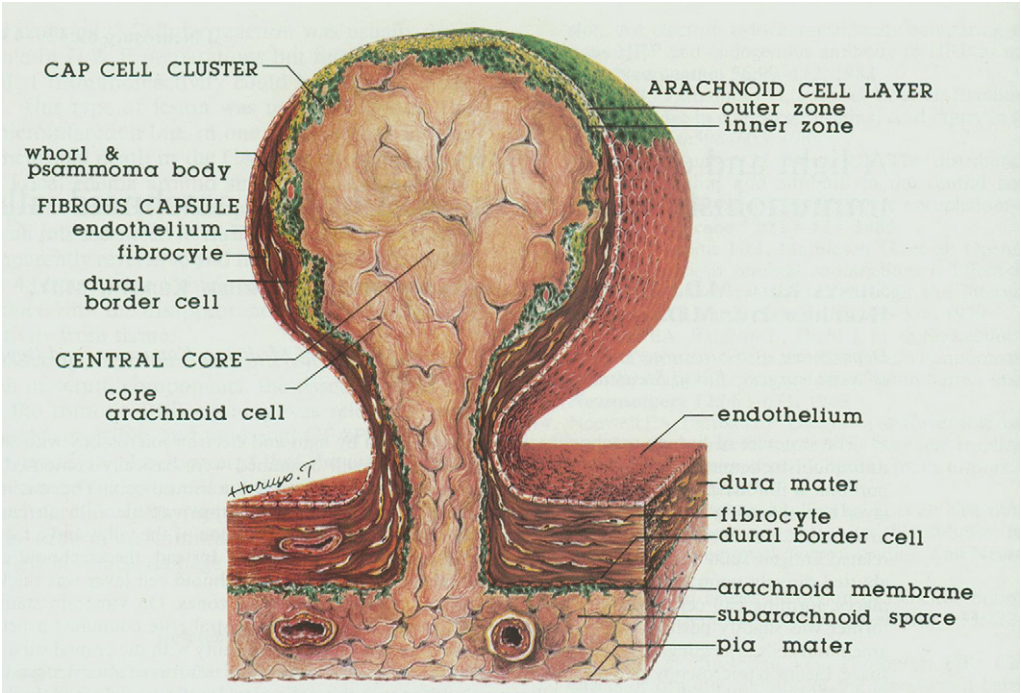

Fig. 1. Structural and morphological characteristics of the human arachnoid granulation.

A study by Kida et al. on human arachnoid granulations demonstrated that they consist of four major parts [27]. A large part of the granulation is made up of the central core, which gives the granulation its shape. The central core is contiguous with the subarachnoid space and is composed of arachnoid cells and fibroblasts interspersed in a connective tissue matrix. An arachnoid cell layer of the granulation is continuous with the underlying arachnoid membrane. A fibrous capsule, reflected from the surrounding dura mater, covers the arachnoid cell layer except at the apical portion of the granulation. The fibrous capsule is composed of several cell types, including vascular endothelial cells from the venous lumen and connective tissue fibers interspersed with fibroblasts from the dura mater. Finally, an arachnoid cap cell layer covers the apical portion of the granulation and directly contacts the venous lumen. The structural characteristics of the arachnoid granulation can be seen in Fig. 1.

The arachnoid granulation cap cell layer seems unique to human arachnoid anatomy. A 2002 study by Ohta et al. compared arachnoid granulations of humans with other primates and canine species [34]. This work confirmed previous reports [1,40,41,44] that found arachnoid granulations of primates and canines are completely invested with an endothelial covering from the venous lumen. In contrast, human arachnoid granulations showed a cap cell layer in direct contact with the venous lumen. These results were in agreement with previous ultrastructural studies of human arachnoid granulations [13,27,45,51–53]. The presence of a cell layer that contacts both the CSF and venous blood, along with the location of the arachnoid cap cells at the apical portion of the granulation, suggests the possibility of a specialized functional role for these cells in the outflow of CSF in humans.

Contemporary research has continued to focus on arachnoid cap cells. The arachnoid cap cells are inherently challenging to study *in vivo* in humans due to their intracranial/intravascular location. Thus, an *in vitro* model has been developed using cultured arachnoid cap cells to study their structural and physiological characteristics [18]. The hydraulic conductivity across a monolayer of these cells was studied under conditions of physiologic and nonphysiologic direction of flow. It demonstrated that AG cells *in vitro* show a statistically significant increase in flow rate and cellular hydraulic conductivity when perfused in the physiologic versus the nonphysiologic direction under normal pressure. The results of these perfusion studies suggest that this *in vitro* model of the AGs can accurately replicate the unidirectional flow of CSF *in vivo*. Further, this model will be used to evaluate the effects of increased pressure and etiologic agents purported to cause raised intracranial pressure (i.e., tetracycline, vitamin A) as well as pharmaceutical agents, which may improve hydraulic conductivity across this cell layer. Initial results from retinol exposure to arachnoidal cells show a statistically reduced cell proliferation rate with increasing concentrations of retinol when compared to cells in serum-free media while fibronectin expression remained the same under the same conditions. Preliminary tests showed that exposing arachnoidal cells to the same concentrations of retinol produced no change in cell viability over 6 days in culture [20].

An innovative method has also been developed to study the topographic distribution of AG on the cerebral cortex as well as the surface area of the arachnoid cap cells [17]. The topographic distribution of AG on the cerebral cortex is depicted in Fig. 2. This ongoing study will assess variables such as gender, age, race, and disease on AG distribution and arachnoid cap cell layer surface area. This will build on previous work by Le Gros Clark and Upton et al., and greatly expand the potential applications of the *in vitro* model, allowing extrapolation of AG cap cell monolayer data to the entire cerebral cortex [29,45,18,17].

3. The lymphatic pathway of cerebrospinal fluid drainage

3.1. Introduction

Though recognized since the early descriptions by Gasparo Aselli as lactae venae (milky veins) in 1627, the true significance of the lymphatic system and its important role in the body's immunological functions is relatively recent. Schwalbe (1869) first postulated that lymphatic channels were significantly involved in the out-

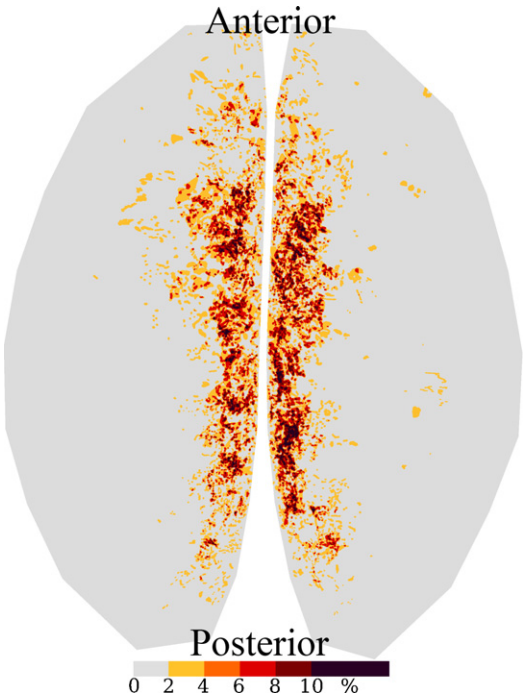

Fig. 2. Topographic distribution map using data from 35 brains showing the probability of an AG occurring at each specific pixel on the standard transformed brain template. AGs have a characteristic distribution along the longitudinal fissure. Darkest color in the scale denotes AGs were identified at that pixel in greater than 10% of the analyzed brains. Each progressively lighter color represents a smaller percentage of cases have an AG at that pixel as indicated by the scale.

flow of CSF [39]. Lymphatic channels transport lymph, a clear fluid with constituents similar to plasma (e.g. proteins, fats, and lymphocytes), and filter it through collections of lymph nodes before draining it to the venous system. These lymph nodes are organized collections of lymphatic tissue that provide immune surveillance and produce lymphocytes and plasma cells. Macrophages are also present in lymph nodes, and play a central role in phagocytosis of bacteria drained from any area of infection.

The lymphatic capillaries begin blindly in most vascularized tissues, and are responsible for the collection of extracellular tissue fluid. They eventually join to form collecting vessels that pass to regional lymph nodes.

Despite their important role played in the systemic lymphatic system, no lymphatic capillaries are recognized in the brain. Yet, there is good evidence that the lymphatic system has a role in the drainage of cerebrospinal fluid from intracranial spaces. From the 1876 work of Key and Retzius, it has been apparent that lymphatic drainage has at least a potential significant role in the outflow of CSF [24]. Key and Retzius (1876) injected colored gelatine into the subarachnoid space of human cadavers and found that it appeared in the cervical lymphatics as well as in the arachnoid granulations [25]. This initial study verified a role for the lymph system, but the actual drainage pathways remained to be shown. Subsequent work (as detailed in Table 1) has confirmed and expanded these findings.

3.1.1. *The pathways of lymphatic CSF drainage*

Decades later, Weed only briefly mentioned the lymphatic pathways in his discussion of CSF outflow, suggesting their contribution as “only a very small portion” in the task of CSF drainage [46]. However, work continued by Faber in 1937, who observed an extension of pial and arachnoid tissues around the olfactory bulb and the olfactory nerve trunk [14]. The persistence of the subarachnoid space beyond the cranial vault and along the olfactory nerve (CN I) was suggested for the first time.

Brierley and Field injected a suspension of carbon particles of varying sizes into the lateral cerebral ventricles of rabbits and found tracer particles clustered in nerve roots of the lumbosacral and cervical regions, indicating that lymphatic CSF drainage was not restricted to cervical lymph nodes [8]. They also proposed that CSF escapes into lumbar lymph nodes of the rabbit through spinal arachnoid fissures and/or permeability by the dura-arachnoid layer to the epidural layer, and from this layer into the lymphatics. This method of CSF egress was also implicated in the rabbit olfactory nerve.

Czerniawska in 1970 injected Au^{98} into rabbit nasal mucosa then found tracer in CSF, an important finding to verify the potential for retrograde passage from nasopharyngeal tissue back into central nervous system tissues [12].

An important study by Arnold in 1972 showed the role of the subarachnoid space around the acoustic nerve in the drainage of CSF in mice, rats, guinea-pigs, and rabbits [2]. Injected ink particles and Thorotrast reached the cisterna magna and the perilymphatic aqueduct, passing along the subarachnoid space of the acoustic nerve to appear in the perilymphatic fluid spaces of the inner ear. The tracer could be followed out of the perilymph of the scala tympani in the region of the round window in extracellular spaces and lymph vessels of the middle ear mucous membrane, eventually draining into the retroauricular lymph nodes.

In 1993, Kida et al. injected India ink into the cisterna magna of rats and found it later in the optic nerve subarachnoid space as well as the cochlea [26]. However, the ink particles communicated directly only with the lymph of the nasal mucosa and those associated lymphatics. This suggested the relative importance of the olfactory lymphatic pathway.

A complete description of the CSF lymphatic drainage pathways in sheep was provided in 1996 by Boulton et al., elaborating the role of the olfactory nerve, the optic nerve, and the acoustic nerve in CSF drainage toward the retropharyngeal lymph nodes [6]. The cranial and spinal nerves were surrounded by a sleeve of pia-arachnoid, accompanied by the persistence of a subarachnoid space. Prominent subarachnoid spaces were particularly described in the olfactory, optic, and acoustic nerves.

Further studies confirmed that the perineural sheath along the olfactory nerve especially represents a major pathway of lymphatic CSF drainage [33]. Using sheep, Silver et al. in a 2002 study, obstructed the cribriform plate, and showed a reduction in CSF volumetric transport, along with an increase in intracranial pressure and outflow resistance [42]. They proposed that CSF first gains access to drainage sites along the base of the cranium, and as intracranial pressure increases, CSF flow may move to the subarachnoid spaces along the convexity of the brain to absorption sites associated with cranial venous sinuses.

Zakharov et al. (2003) injected a silicone compound (Microfil) into the subarachnoid space to delineate the lymphatic (in contrast to the arteriolar) pathways in lambs [54]. Prominent filling of many cranial nerves was observed, including the trigeminal, facial, glossopharyngeal, vagal, and hypoglossal, suggesting that these nerves contribute to CSF lymphatic drainage. The highest density of contrast agent was observed in extensive lymphatic networks in nasal submucosa covering the hard and soft palate, conchae, nasal septum, and ethmoid labyrinth and lateral walls of nasal cavity. This confirmed CSF uptake at multiple nasopharyngeal locations, with extensive communication between CSF and lymph nodes.

Recent studies have injected Microfil into the subarachnoid space of several species, including humans, later observing the Microfil in an extensive lymphatic network, especially around the olfactory nerves at the level of the cribriform plate [55]. Additional

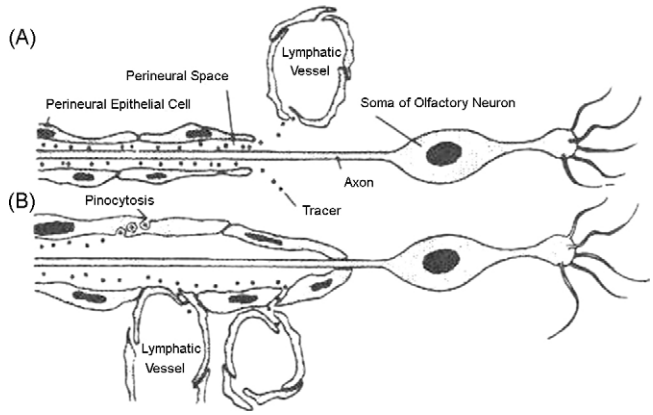

Fig. 3. Schematic illustration of two models that could be used to explain movement of tracers in and out of the perineural space to lymphatic vessels. For simplicity only one olfactory axon is shown within the perineural space; actual number is not known. A, open-cuff model; B, closed-cuff model.

studies have blocked CSF drainage at the cribriform plate in sheep and observed subsequent increases in intracranial pressure, further suggesting the importance of this pathway in CSF drainage [42].

An important study on the dynamics of perineural CSF drainage in rats was done in 1997 by Brinker et al. [9]. They showed that the olfactory nerve drained first, followed by the optic nerve a few minutes later, then followed by the inner ear, cortical sinuses, and transverse sinuses. It was also demonstrated that lymphatic drainage cycled from 10 to 20 mm/s with inspiration, to zero with expiration, the first demonstration of cyclical flow of CSF in lymphatic drainage.

CSF egress from perineurial sheaths into the extracellular space and mechanism of lymphatic absorption remain incompletely understood. We understand that CSF flows in the subarachnoid space enclosed by the perineurial sheath. Both open-cuffed and close-cuffed subarachnoid sheaths have been proposed by Jackson et al. (1979) [22]. The open-cuffed model proposes an open end on the sheath allowing the free drainage of CSF to the extracellular space, and absorption by lymphatic capillaries. The close-cuffed model depicts a cul-de-sac surrounding the nerve, and a lymphatic capillary absorbing CSF by pinocytosis. Some studies in rats have also suggested a third possibility involving direct flow of CSF from the subarachnoid space to submucosal lymphatics, especially at the level of the cribriform plate [56]. Depictions of Jackson's proposed mechanisms can be seen in Fig. 3.

A more recent study in 2001 by Kelkenberg et al. has demonstrated the presence of villus-like structures on the distal optic nerve of chickens, connecting the subarachnoid space with accompanying veins [24]. This suggests another avenue of perineurial CSF escape.

In addition to uncertainties surrounding perineural CSF escape, visualization of perineurial CSF drainage is challenging without a proper understanding of basic neuroanatomy. Although an extensive discussion of all cranial nerve pathways is outside the scope of this paper, the microanatomy of the major cribriform pathway of perineurial CSF drainage is outlined below.

Visualization of the olfactory nerve pathway is made especially difficult by its route, which traverses both intracranial and extracranial segments. The olfactory tract leaves the brainstem, follows the floor of the anterior fossa, and expands into the olfactory bulbs. The olfactory nerve fibers exit the cranial vault through cribriform foramina in the cribriform plate of the ethmoid bone. These cribriform foramina are small paramedial punctate openings in the mid-anterior fossa floor carrying olfactory nerve fibers from the cranial vault to the roof of the nasal cavity. After penetrating the cribriform foramina, the olfactory nerve fibers enter the nasal mucosa in the roof of the nasal cavity, where they terminate in approximately 20 bundles per side. At this point the CSF drains from the perineural subarachnoid space into the extracellular matrix, where it is absorbed by blind-ended lymphatic capillaries, and drained to the regional lymph nodes that serve the nasopharynx.

3.1.2. *Quantitative analysis of CSF outflow*

Courtice and Simmonds in 1951 "injected plasma labeled with Evans Blue dye into the cisterna magna of cats and rabbits and showed that the labeled proteins appeared in blood plasma" and in the lymph [11]. The amount in lymph was much less than the amount found in plasma, providing the first quantitative CSF outflow assessment.

In 1980, Bradbury and Cole provided additional quantitative information by injecting radio-iodinated albumin and fluorescent dextran into the lateral ventricles of rabbits and cats [7]. They showed that 30% of CSF in rabbits and 10–15% in cats was drained via the lymphatic system.

In 1998, an important contribution was offered by Boulton et al. [5]. By infusion of iodine-labeled serum human albumin into sheep, it was determined that 40–48% of total volume of CSF is absorbed from the cranial compartment by extracranial lymphatics. In 1999 Boulton et al. went on to compare rats and sheep in this regard. Despite the much higher turnover rate of rats when compared to sheep, the proportion of CSF drained through extracranial lymphatics remained the same. This suggested that CSF clearance was independent of turnover rate.

More recent work has focused on neonatal and fetal CSF drainage. In 2001, despite the paucity of visible arachnoid granulations in sheep fetuses and newborns, Mollanji et al. showed that "global CSF transport parameters in the late gestation fetus and adult sheep are similar." [33]

Sealing the cribriform pathway in neonatal and adult sheep showed a significant decrease in CSF outflow in both [33,37]. However intracranial CSF still cleared, suggesting again, alternative drainage routes other than the olfactory, and possibly via functioning arachnoid granulations.

Le Gros Clark (1920) noted that the arachnoid granulations increase in number in children until they become visible by approximately eighteen months [29]. There is also evidence that the surface area of the cribriform foramina decreases with age. Such findings fit with a dual system of CSF outflow, with arachnoid granulations assuming increasing responsibility of CSF drainage as they grow in size and number with age.

4. Transependymal contributions to cerebrospinal fluid drainage

Among the surprising benefits of the clinical application of magnetic resonance imaging (MRI) was the revelation of "water" passage into the periventricular tissues of the intact brain, under high intraventricular pressure. Neuroimaging of patients with ventricular obstruction, and even with idiopathic intracranial hypertension, showed the MRI signal indicative of transependymal passage of CSF. Increased intracranial pressure forces cerebrospinal fluid across the ependymal barrier and into the extracellular space of adjacent periventricular white matter [43,16]. This provides an additional, though unexpected, pathway for CSF flow under such abnormal circumstances. Although this is not a true mechanism of CSF outflow, it is a mechanism of CSF escape from the subarachnoid space that correlates with the normal to small sized ventricles noted on neuroradiologic imaging studies in patients with idiopathic intracranial hypertension. This finding is in contradistinction

to the dilated ventricles seen in patients with obstructive hydrocephalus.

Diffusion tensor MRI is a technique used to study water diffusion in tissue [15,3]. This technique may be more sensitive than standard MRI to show increased water mobility via the transependymal pathway. Further studies are needed in order to properly evaluate the utility of this modality in patients with raised intracranial pressure.

5. Discussion

Current information about the multiple possibilities for CSF outflow in other species suggests that we consider the potential for similar pathways in man. Although most of us know of the traditional AG pathway, fewer of us are as familiar with the major alternative route through the anterior cranial base, especially that via the olfactory channels into the nasopharyngeal lymphatics.

The arachnoid granulations have been studied extensively, but our understanding of their role in CSF outflow remains limited. At this point, research has predominantly focused on anatomic characterization of the arachnoid granulation. Some studies have shown definitively that the arachnoid granulations do provide an avenue for CSF outflow; however, more research is needed in humans to identify the precise mechanism of egress. Furthermore, quantitative data are needed to determine the extent to which these pathways are utilized in conditions of normal vs. elevated intracranial pressure. Isotope studies, which are frequently used clinically in studying central nervous system shunts and normal pressure hydrocephalus, may provide one avenue for possible quantitative evidence of this outflow pathway.

The lymphatic pathway has been shown to provide drainage for 40–50% of CSF in rodents and sheep. A similar potential may exist in man, especially in early life, prior to the appearance of recognizable arachnoid villi and arachnoid granulations. If this nasopharyngeal lymphatic route does play a role, then failure of this route can help explain the clinical aspects of pediatric hydrocephalus, with its age of onset and cranial distortion, and can be very separate from what may later become the more important arachnoid granulation pathway later in life [19].

In related fashion, acquired impairment of AG function due to injury, infection, inflammation, or genetic predisposition, could help explain increased intracranial pressure responses to particulate obstruction with red blood cells in subarachnoid hemorrhage, or to meningeal irritation with viral/bacterial meningitis [10,28,30,49]. This perspective is particularly applicable to pressure rises that may follow the metabolic failure of CSF transport across the arachnoid-endothelial barriers due to genetic predisposition (i.e., idiopathic intracranial hypertension), and to the toxic responses of increased intracranial pressure seen with vitamin A [50] and assorted antibiotics in the many secondary pseudotumors. Because of the relationship of the venous drainage pathways to the adjacent AGs, many other secondary CSF pressure increases are responses to venous pressure increases at the cranial and cranial outflow levels. Venous outflow obstruction may occur at many levels, including jugular vein occlusions, cortical vein thromboses, and even venous microthrombi seen in the coagulopathies that may be part of the systemic lupus erythematosis syndrome [36,21,38], and known to be present in renal glomeruli.

Finding red blood cells (RBCs) in the arachnoid granulation channels after subarachnoid hemorrhage confirms a role for these channels for CSF outflow in adults [4,10]. A search for similar RBC markers in olfactory-cribriform-lymphatic channels after subarachnoid hemorrhage in adults, and especially in children, would help us to clarify such an alternative role in man.

This field of interest remains dynamic. Review of the available literature on CSF outflow back to 1869, leads to an awareness not only of routes through the AGs, but the presence of alternative routes of flow via perineural sheaths through the cranial base, through spinal nerves, and even across ependymal surfaces. Because the interplay of these two outflow pathways remains poorly understood, their further study is warranted. Ultimately, the study of all anatomic regions known to play a role in CSF egress will be required with a combination of study techniques (i.e., *in vivo* and *in vitro*, animal and human models), by multi-disciplinary groups of researchers. Understanding CSF egress under both physiologic and pathologic conditions will lead to more clear classifications and better treatment of diseases associated with intracranial hypertension and other disorders of CSF homeostasis.

Conflict of interest

Authors confirm that the present manuscript complies with ethical standards and we declare no conflicts of interest exist.

Acknowledgements

The authors are thankful to the Ohio Lions Eye Research Foundation, the Davis Medical Research Grant, and the Fight for Sight Research Awards Program for supporting this research.

References

[1] J.F. Alksne, E.T. Lovings, Functional ultrastructure of the arachnoid villus, Arch. Neurol. 27 (5) (1972) 371–377.
[2] W. Arnold, H.R. Nitze, R. Ritter, C. von Ilberg, U. Ganzer, Qualitative study of the connections of the subarachnoid space with the lymphatic system of the head and neck, Acta Otolaryngol. 74 (December (6)) (1972) 411–424.
[3] M.E. Bastin, S. Sinha, A.J. Farrall, J.M. Wardlaw, I.R. Whittle, Diffuse brain oedema in idiopathic intracranial hypertension: a quantitative magnetic resonance imaging study, J. Neurol. Neurosurg. Psychiatry 74 (December (12)) (2003) 1693–1696.
[4] J. Benito-Leon, P.G. Leon, A. Ferriero, J. Martinez, Intracranial hypertension syndrome as an unusual form of presentation of spinal subarachnoid hemorrhage and subdural haematoma, Acta Neurochir. (Wien) 139 (3) (1997) 261–262.
[5] M. Boulton, D. Armstrong, M. Flessner, J. Hay, J.P. Szalai, M. Johnston, Raised intracranial pressure increases CSF drainage through arachnoid villi and extracranial lymphatics, Am. J. Physiol. 275 (1998) R889–R896.
[6] M. Boulton, A. Young, J. Hay, D. Armstrong, M. Flessner, M. Schwartz, M. Johnston, Drainage of CSF through lymphatic pathways and arachnoid villi in sheep: measurement of 125 I-albumin clearance, Neuropathol. Appl. Neurobiol. 22 (4) (1996) 325–422.
[7] M.W.B. Bradbury, D.F. Cole, The role of the lymphatic system in drainage of cerebrospinal fluid and aqueous humour, J. Physiol. 299 (1980) 353–365.
[8] J.B. Brierley, E.J. Field, The connexions of the spinal sub-arachnoid space with the lymphatic system, J. Anat. 82 (1948) 153–166.
[9] T. Brinker, W. Ludemann, D.B. Rautenfeld, M. Samii, Dynamic properties of lymphatic pathways for the absorption of cerebrospinal fluid, Acta Neuropathol. 94 (1997) 493–498.
[10] T. Brinker, V. Seifert, D. Stolke, Acute changes in the dynamics of the cerebrospinal fluid system during experimental subarachnoid hemorrhage, Neurosurgery 27 (3) (1990) 369–372.
[11] F.C. Courtice, W.J. Simmonds, The removal of protein from the subarachnoid space, Aust. J. Exp. Biol. Med. Sci. 29 (1951) 255–263.
[12] A. Czerniawska, Experimental investigations on the penetration of 198Au from nasal mucous membrane into cerebrospinal fluid, Acta Otolaryngol. 70 (1) (1970) 58–61.
[13] D. D'Avella, R. Cicciarello, G. Andrioli, Scanning electron microscope study of human arachnoid villi, J. Neurosurg. 59 (4) (1983) 620–626.
[14] W.M. Faber, The nasal mucosa and the subarachnoid space, Am. J. Anat. 62 (1937) 121–148.
[15] P. Gideon, P.S. Sorensen, C. Thomsen, F. Stahlberg, F. Gjerris, O. Henriksen, Increased brain water self-diffusion in patients with idiopathic intracranial hypertension, AJNR Am. J. Neuroradiol. 16 (February (2)) (1995) 381–387.
[16] P. Gideon, G. Thomsen, F. Gjerris, P.S. Sorensen, O. Henriksen, Increased self-diffusion of brain water in hydrocephalus measured by MR imaging, Acta Radiol. 35 (November (6)) (1994) 514–519.
[17] D.M. Grzybowski, E.E. Herderick, K.G. Kapoor, D.W. Holman, S.E. Katz, Human arachnoid granulations Part I: a technique for quantifying area and distribution on the superior surface of the cerebral cortex, Cerebrospinal Fluid Res. 4 (July (6)) (2007).

[18] D.M. Grzybowski, D.W. Holman, S.E. Katz, M. Lubow, *In vitro* model of cerebrospinal fluid outflow through human arachnoid granulations, Invest. Ophthalmol. Vis. Sci. 47 (August (8)) (2006) 3664–3672.
[19] P.W. Hanlo, R.J. Gooskens, M. van Schooneveld, C.A. Tulleken, M.S. van der Knaap, J.A. Faber, J. Wilemse, The effect of intracranial pressure on myelination and the relationship with neurodevelopment in infantile hydrocephalus, Dev. Med. Child Neurol. 39 (May (5)) (1997) 286–291.
[20] D.W. Holman, D.M. Grzybowski, The Effect of Vitamin A on Cultured Arachnoid Granulation Cells: Implications for Idiopathic Intracranial Hypertension, North American Neuroophthalmology Society Annual Conference, Orlando, Florida, 2008, Orlando, Florida, 2008.
[21] D. Horoshovski, H. Amital, M. Katz, Y. Shoenfeld, Pseudotumour cerebri in SLE, Clin. Rheumatol. 14 (November (6)) (1997) 708–710.
[22] R.T. Jackson, J. Tigges, W. Arnold, Subarachnoid space of the CNS, nasal mucosa, and lymphatic system, Arch. Otolaryngol. 105 (4) (1979) 180–184.
[23] M. Johnston, C. Papaiconomou, Cerebrospinal fluid transport: a lymphatic perspective, News Physiol. Sci. 17 (2002) 227–230.
[24] U. Kelkenberg, D.B. Rautenfeld, T. Brinker, V.H. Hans, Chicken arachnoid granulations: a new model for cerebrospinal fluid absorption in man, Neuroreport 12 (3) (2001) 553–557.
[25] G. Key, A. Retzius, Studien in der Anatomie des Nervensystems und des Bindesgewebe, Samson and Wallin, Stockholm, 1876.
[26] S. Kida, A. Pantazis, R.O. Weller, Cerebrospinal fluid drains directly from the subarachnoid space into nasal lymphatics in the rat. Anatomy, histology, and immunological significance, Neuropathol. Appl. Neurobiol. 19 (6) (1993) 480–488.
[27] S. Kida, T. Yamashima, T. Kubota, H. Ito, S. Yamamoto, A light and electron microscopic and immunohistochemical study of human arachnoid villi, J. Neurosurg. 69 (1988) 429–435.
[28] M. Koskiniemi, H. Piipaninen, T. Rantalaiho, P. Eranko, M. Farkkila, K. Raiha, E.M. Salonen, P. Ukkonen, A. Vaheri, Acute central nervous system complications in varicella zoster virus infections, J. Clin. Virol. 25 (3) (2002) 293–301.
[29] W.E. Le Gros Clark, On the Pacchionian bodies, J. Anat. 55 (1920) 40–48.
[30] S.L. Leib, M.G. Tuber, Meningitis (I)—differential diagnosis; aseptic and chronic meningitis, Ther. Umsch. 56 (November (11)) (1999) 631–639 (Review, German).
[31] J.E. Levine, J.T. Povlishock, D.P. Becker, The morphological correlates of primate cerebrospinal fluid absorption, Brain Res. 241 (1) (1982) 31–41.
[32] J.G. McComb, Recent research into the nature of cerebrospinal fluid formation and absorption, J. Neurosurg. 59 (3) (1983) 369–383.
[33] R. Mollanji, C. Papaiconomou, M. Boulton, R. Midha, M. Johnston, Comparison of cerebrospinal fluid transport in fetal and adult sheep, Am. J. Physiol. Regulatory Integrative Comp. Physiol. 281 (2001) R1215–R1223.
[34] K. Ohta, T. Inokuchi, Y. Hayashida, T. Mizukami, T. Yoshida, T. Kawahara, Regional diminution of von Willebrand factor expression on the endothelial covering arachnoid granulations of human, monkey, and dog brain, Kurume Med. J. 49 (4) (2002) 177–183.
[35] A. Pacchioni, Dissertationes physico-anatomical de dura meninge humana, novis experimentis et lucubrationibus auctae et eillustratae, A de Rubeis, Roma, 1721.
[36] S. Padeh, J.H. Passwell, Systemic lupus erythematosus presenting as idiopathic intracranial hypertension, J. Rheumatol. 23 (7) (1996) 1266–1268.
[37] C. Papaiconomou, R. Bozanovic-Sosic, A. Zakharov, M. Johnston, Does neonatal cerebrospinal fluid absorption occur via arachnoid projections or extracranial lymphatics? Am. J. Physiol. Regul. Integr. Comp. Physiol. 283 (2002) R869–R876.
[38] S. Sbeiti, D.M. Kayed, H. Majuri, Pseudotumor cerebri presentation of systemic lupus erythematosus: more than an association, Rheumatology (Oxford) 42 (6) (2003) 808–810.
[39] G. Schwalbe, Der Arachnoidalraum ein Lymphraum und sein Zussamenhang mit den Perichoriodalraum, Zentralbl Med. Wiss. 7 (1869) 465–467.
[40] A.L. Shabo, D.S. Maxwell, The subarachnoid space following the introduction of a foreign protein: an electron microscopic study with peroxidase, J. Neuropathol. Exp. Neurol. 30 (3) (1971) 506–524.
[41] A.L. Shabo, D.S. Maxwell, The fine structure of the primate arachnoid villus under normal and experimental conditions, Acta Neurol. Latinoa 1 (Suppl.) (1971) 53–81.
[42] I. Silver, C. Kim, R. Mollanji, M. Johnston, Cerebrospinal fluid outflow resistance in sheep: impact of blocking cerebrospinal fluid transport through the cribriform plate, Neuropathol. Appl. Neurobiol. 28 (2002) 67–74.
[43] P.S. Sorensen, C. Thomsen, F. Gjerris, O. Henriksen, Brain water accumulation in pseudotumour cerebri demonstrated by MR-imaging of brain water self-diffusion, Acta Neurochir. Suppl. (Wien) 51 (1990) 363–365.
[44] R.C. Tripathi, The functional morphology of the outflow systems of ocular and cerebrospinal fluids, Exp. Eye Res. 25 (Suppl.) (1977) 65–116.
[45] M.L. Upton, R.O. Weller, The morphology of cerebrospinal fluid drainage pathways in human arachnoid granulations, J. Neurosurg. 63 (6) (1985) 867–875.
[46] L.H. Weed, The theories of drainage of cerebro-spinal fluid with an analysis of the methods of investigation, J. Med. Res. 31 (1914) 21–117.
[47] K. Welch, V. Friedman, The cerebrospinal fluid valves, Brain 83 (1960) 454–469.
[48] K. Welch, M. Pollay, Perfusion of particles through arachnoid villi of the monkey, Am. J. Physiol. (1961) 651–654.
[49] R.O. Weller, Pathology of cerebrospinal fluid and interstitial fluid of the central nervous system: significance for Alzheimer's disease, prion disorders, and multiple sclerosis, J. Neuropathol. Exp. Neurol. 57 (10) (1998) 885–894.
[50] L.J. Wilkoff, J.C. Peckham, E.A. Dulmadge, R.W. Mowry, D.P. Chopra, Evaluation of vitamin A analogs in modulating epithelial differentiation of 13-day chick embryo metatarsal skin explants, Cancer Res. 36 (3) (1976) 964–972.
[51] E.R. Wolpow, H.H. Schaumburg, Structure of the human arachnoid granulation, J. Neurosurg. 37 (6) (1972) 724–727.
[52] T. Yamashima, Ultrastructural study of the final cerebrospinal fluid pathways in human arachnoid villi, Brain Res. 384 (1) (1986) 68–76.
[53] T. Yamashima, Functional ultrastructure of cerebrospinal fluid drainage channels in human arachnoid villi, Neurosurgery 22 (4) (1988) 633–641.
[54] A. Zakharov, C. Papaiconomou, J. Djenic, R. Midha, M. Johnston, Lymphatic cerebrospinal fluid absorption pathways in neonatal sheep revealed by subarachnoid injection by Microfil, Neuropathol. Appl. Neurobiol. 29 (2003) 563–573.
[55] A. Zakharov, C. Papaiconomou, M. Johnston, Lymphatic vessels gain access to cerebrospinal fluid through unique association with olfactory nerves, Lymphat. Res. Biol. 2 (2004) 139–146.
[56] E.T. Zhang, H.K. Richards, S. Kida, R.O. Weller, Directional and compartmentalized drainage of interstitial fluid and cerebrospinal fluid from the rat brain, Acta Neuropathol. (Berl.) 83 (1992) 233–239.